



## FORENSIC MEDICAL ASSESSMENT OF KIDNEY DAMAGE DURING BLUNT OBJECT INJURY

**Shakirov Sardor Abdusaminovich**

Candidate (DSc)

Scientific consultant: **Ruziev Sherzod Ibadullaevich**

Doctor of Medical Sciences, Professor

### Abstract

The article presents the relevance, current state and prospects of issues of forensic medical assessment of lifetime, limitation and the mechanism of formation of damage to parenchymal organs in closed blunt abdominal trauma.

### Keywords

Closed blunt abdominal trauma, expert assessment, isolated injuries of the parenchymal organs of the abdomen, lifetime, duration, mechanism of formation.

### INTRODUCTION

The formation of injuries to the parenchymal organs of the abdomen with blunt objects is a closed blunt trauma of the abdomen, which, according to the existing definition, constitutes a complex of injuries to the internal organs of the abdomen and retroperitoneal space in the absence of signs of damage to the integrity of the skin of the abdomen, lower chest and lumbar region [1, 3]. Injury to the parenchymal organs of the abdomen is associated with transport accidents, cases of falling from a height and the impact of blunt objects with a limited impact surface. A frequent complication of these injuries is the rapid development of massive blood loss and hemorrhagic shock, and in a later period, peritonitis. Mortality from injuries to the parenchymal organs of the abdomen in cases of combined body trauma ranges from 55.5 to 81.5% of cases [2]. With isolated trauma to the parenchymal organ of the abdomen, deaths account for up to 20% [4]. The first place in the frequency of injuries to abdominal organs is occupied by parenchymal organs - liver, spleen, kidneys.

### MATERIALS AND METHODS

Isolated kidney injuries in closed blunt abdominal trauma occur in 6 to 20.1%. In the forensic medical literature there are isolated works in which the authors describe the main types of deformation experienced by an organ when determining the direction of traumatic impact and the properties of traumatic objects, and also provide an expert assessment of the characteristics of the resulting injuries (localization of ruptures, orientation and propagation in depth) [2,3].

O.A. Sakovchuk identified reliable morphological signs of kidney ruptures, reflecting the characteristics of the deformation of the organ at the time of injury. The author found that the deformation experienced by the kidney during blunt trauma is accompanied by stretching of the organ parenchyma and is characterized by the formation of ruptures with smooth, steep, comparable edges, while ruptures of the capsule correspond to ruptures of the parenchyma; the walls of the



resulting gaps reflect the structure of the kidney in the form of columns. The process of compression of renal tissue during its deformation is characterized by the formation of tears with uneven edges that have signs of crushing; ruptures of the capsule do not correspond to ruptures of partially structureless parenchyma with isolated areas preserving the columnar structure [1].

## RESULTS AND DISCUSSION

O.A. Sakovchuk, while performing his work, assessed reactive changes in the kidney during blunt trauma in the experiment and in cases from expert practice, which made it possible to identify characteristic intravital pathomorphological changes, to which the author included post-traumatic hemorrhages, disruption of the structure of the glomeruli, tubules and vessel walls, as well as the formation of hemorrhages in the glomerular capsule, anemia and collapse of the capillaries of the glomerular loops, the presence of blood in the lumen of the distal and proximal tubules, acute circulatory disorders with the formation of microthrombi. The second important issue during the work was the establishment of the morphodynamics of inflammatory changes in the kidney after blunt trauma. At the same time, the author conducted a comparative assessment of pathomorphological changes in soft tissues and kidneys in cases from expert practice, which made it possible to establish more pronounced dynamics of reactive and inflammatory changes in hypovolemia caused by blood loss and shock compared to the normovolemic state [1].

According to M.A. Sapozhnikova, trauma to the pancreas is observed in car accidents (41.5% of cases), in cases of falling from a great height (11.6%), severe compression of the body by blunt objects or when impacted by blunt objects in the epigastric region of the abdomen (to 10%). The resulting injury, as a rule, is of a combined nature with injuries to the liver, spleen, stomach and duodenum, kidneys, mesentery of the small intestine, and fractures of the ribs of the left costal arch.

## CONCLUSION

Thus, at present, general questions have been developed to establish the mechanisms of formation of damage to the parenchymal organs of the abdomen during trauma with blunt objects. Conducting further research, in our opinion, may be associated with the conduct and implementation into expert practice of results based on the use of methods of mathematical processing of morphological signs of damage to the abdominal organs in order to establish the features of the interaction of a traumatic object with the human body, which will make it possible to objectify the expert's conclusions and improve the quality of forensic medical examinations.

The development of issues of establishing the lifetime and duration of injury to the parenchymal organs of the abdomen is far from a final solution due to the fact that the information available in the literature is not sufficiently systematized and is often contradictory. In this regard, further scientific research on the issue under consideration is relevant and significant for expert practice.

## REFERENCES

1. Sakovchuk O.A. Pathomorphological assessment of kidney damage at various times in the post-traumatic period: dis. ...cand. honey. Sci. – Novosibirsk, 2014. – 124 p.



ResearchGate

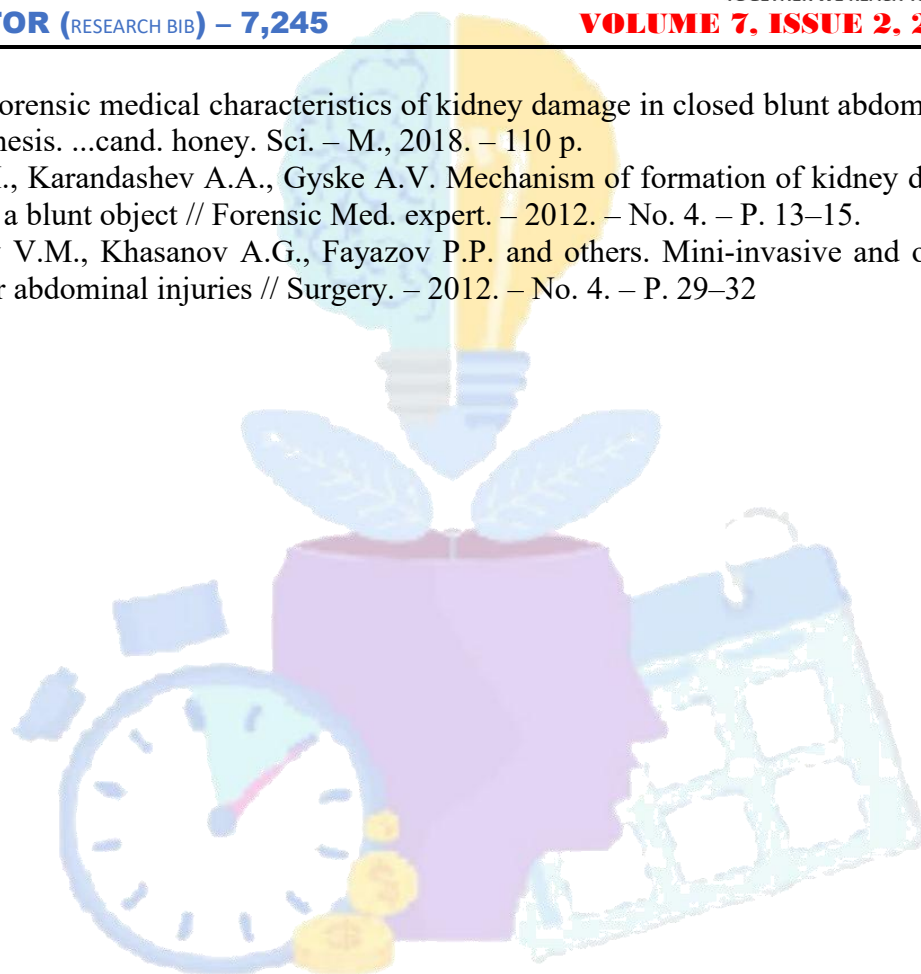


TOGETHER WE REACH THE GOAL

**IMPACT FACTOR (RESEARCH BIB) – 7,245**

**VOLUME 7, ISSUE 2, 2024**

2. Giske A.V. Forensic medical characteristics of kidney damage in closed blunt abdominal trauma: dissertation thesis. ...cand. honey. Sci. – M., 2018. – 110 p.
3. Sosedko Yu.I., Karandashev A.A., Gyske A.V. Mechanism of formation of kidney damage from the impact of a blunt object // Forensic Med. expert. – 2012. – No. 4. – P. 13–15.
4. Timerbulatov V.M., Khasanov A.G., Fayazov P.P. and others. Mini-invasive and organ-saving operations for abdominal injuries // Surgery. – 2012. – No. 4. – P. 29–32



# WORDLY KNOWLEDGE